

1

2 **Reinfection could not occur in SARS-CoV-2 infected rhesus macaques**

3

4 Linlin Bao^{†,1}, Wei Deng^{†,1}, Hong Gao^{†,1}, Chong Xiao^{†,1}, Jiayi Liu^{†,2}, Jing Xue^{†,1}, Qi
5 Lv^{†,1}, Jiangning Liu¹, Pin Yu¹, Yanfeng Xu¹, Feifei Qi¹, Yajin Qu¹, Fengdi Li¹, Zhiguang
6 Xiang¹, Haisheng Yu¹, Shuran Gong¹, Mingya Liu¹, Guanpeng Wang¹, Shunyi Wang¹,
7 Zhiqi Song¹, Wenjie Zhao¹, Yunlin Han¹, Linna Zhao¹, Xing Liu¹, Qiang Wei¹, Chuan
8 Qin^{*,1}

9

10 ¹Beijing Key Laboratory for Animal Models of Emerging and Remerging Infectious
11 Diseases, NHC Key Laboratory of Human Disease Comparative Medicine, Institute of
12 Laboratory Animal Science, Chinese Academy of Medical Sciences and Comparative
13 Medicine Center, Peking Union Medical College, Beijing, China; ²Department of
14 Radiology, Beijing Anzhen Hospital, Capital Medical University

15

16 [†]These authors contributed equally to this work.

17 ^{*}Correspondence should be addressed to Chuan Qin, Email: qinchuan@pumc.edu.cn.

18

Abstract

An outbreak of the Corona Virus Disease 2019 (COVID-19), caused by the severe acute respiratory syndrome CoV-2 (SARS-CoV-2), began in Wuhan and spread globally. Recently, it has been reported that discharged patients in China and elsewhere were testing positive after recovering. However, it remains unclear whether the convalescing patients have a risk of “relapse” or “reinfection”. The longitudinal tracking of re-exposure after the disappeared symptoms of the SARS-CoV-2-infected monkeys was performed in this study. We found that weight loss in some monkeys, viral replication mainly in nose, pharynx, lung and gut, as well as moderate interstitial pneumonia at 7 days post-infection (dpi) were clearly observed in rhesus monkeys after the primary infection. After the symptoms were alleviated and the specific antibody tested positively, the half of infected monkeys were rechallenged with the same dose of SARS-CoV-2 strain. Notably, neither viral loads in nasopharyngeal and anal swabs along timeline nor viral replication in all primary tissue compartments at 5 days post-reinfection (dpr) was found in re-exposed monkeys. Combined with the follow-up virologic, radiological and pathological findings, the monkeys with re-exposure showed no recurrence of COVID-19, similarly to the infected monkey without challenge. Taken together, our results indicated that the primary SARS-CoV-2 infection could protect from subsequent exposures, which have the reference of prognosis of the disease and vital implications for vaccine design.

The Corona Virus Disease 2019 (COVID-19) caused by severe acute respiratory syndrome CoV-2 (SARS-CoV-2), emerged in Wuhan China, has continued to sweep through South Korea, Japan, Italy and Iran. More than 90,000 people have been infected worldwide, with nearly 3000 deaths in about 40 countries^{1,2}. Since February, it was estimated that about 14% of discharged patients in Guangdong province and elsewhere were testing positive after their release from the hospital and had to return to the hospital for observation^{3,4}. Doubts about whether patients have a risk of "relapse" or "reinfection" after recovery from initial infection have aroused the worldwide concern. Therefore, in this study, we used the nonhuman primate models with SARS-CoV-2 infection followed by the same virus rechallenge to ascertain the possibility of reinfection.

Four adult Chinese rhesus macaques (No M1-M4, 3-5 kg, 3-5-year-old) were intratracheally challenged with SARS-CoV-2 at 1×10^6 50% tissue-culture infectious doses (TCID₅₀), and the body weight, body temperature, X-ray, sampling of sera, nasal/throat/anal swabs and all primary tissues were carried out on schedule (Figure 1). Following the initial infection, three of the four monkeys showed the weight loss ranging from 200 g to 400 g (Figure 2a), but the changes of rectal temperature in all the animals were not observed (Figure 2b). Other clinical signs such as reduced appetite, increased respiration rate and hunched posture were transient after the initial challenge. We next determined their viral loads in respiratory and anal swabs along the timeline after the infection. As shown in Figure 2c and 2d, the viral loads in nasal swabs and pharyngeal swabs reached the highest levels (average, approximately $6.5 \log_{10}$ RNA copies/mL) at 3 days post-infection (dpi) and then declined naturally. Similarly, viral loads from anal swabs reached the peak about $4.5 \log_{10}$ RNA copies/mL at 3 dpi and then declined to undetectable level at 14 dpi (Figure 2e). To identify the virus

65 distribution and histopathological changes in SARS-CoV-2 infected monkeys, M1
66 monkey was euthanized and necropsied at 7 dpi. As shown in Figure 2f (left panel),
67 viral replication was found in nose (10^7 to 10^8 copies/mL), pharynx (10^5 to 10^6
68 copies/mL), lung (10^4 to 10^7 copies/mL), gut (10^4 to 10^6 copies/mL), spinal cord
69 (approximately 10^4 copies/mL), heart (approximately 10^4 copies/mL), skeletal muscle
70 (approximately 10^4 copies/mL) and bladder (approximately 10^4 copies/mL).
71 Furthermore, the lesions occurred mainly in the lung confirmed by the HE staining and
72 anti-spike protein of SARS-CoV-2 staining, with mild to moderate interstitial
73 pneumonia characterized by thickened alveolar septa, accumulation of alveolar
74 macrophages in the alveoli, degeneration of the alveolar epithelia, and infiltration of
75 inflammatory cells (Figure 3a). In addition, the chest X-ray at 7 dpi showed that the
76 upper lobe of the right lung had varying degrees of the localized infiltration and
77 interstitial markings, showing the mild to bilateral ground-glass opacification
78 (Represented by M4, Figure 3b). For the longitudinal tracking of the characteristics
79 each monkey, the specific antibody against SARS-CoV-2 of M2, M3 and M4 monkey
80 was significantly elevated at 14 dpi or 21 dpi and 28 dpi compared to that at 3 dpi and
81 7dpi ($*P<0.05$, $**P<0.01$, Figure 2g). In the three infected monkeys alive, body weight
82 and rectal temperature remained relatively stable before rechallenge (Figure 2a and 2b),
83 viral loads of nasopharyngeal and anal swabs were not detectable along the timeline
84 before 28 dpi (Figure 2c to 2e), and no common abnormalities were found on a chest
85 X-ray test at 28 dpi prior to the rechallenge (Represented by M4, Figure 3b). Altogether,
86 these data suggested that the three animals were considered as recovering from SARS-
87 CoV-2 infection, similarly meeting the clinical discharge evaluation criteria (absence
88 of clinical symptoms and radiological abnormalities and 2 negative RT-PCR test
89 results⁵).

Subsequently, two infected monkeys (M3 and M4) were intratracheally re-challenged at 28 dpi with the same dose (1×10^6 TCID₅₀) of SARS-CoV-2 to ascertain the possibility of reinfection, whereas M2 monkey without any re-treatment was continuously monitored as the control (Figure 1). None of the monkeys showed the weight loss after the re-exposure (Figure 2a), but the transient elevation of body temperature was observed in both re-exposed monkeys (Figure 2b). Viral loads in nasopharyngeal and anal swabs tested negative after the re-exposure of SARS-CoV-2 along the timeline (Figure 2c to 2e). Correspondingly, M3 monkey was euthanized and necropsied at 5 days post-reinfection (dpr) to confirm the viral replication and histopathological changes caused by re-exposure. Compared to M1 monkey at 7 dpi, no viral replication in all tissues (Figure 2f, right panel), as well as no pathological damage and viral antigen in lung tissues (Figure 3a, lower panel), were found in M3 monkey at 5 dpr. As shown in Figure 3b, chest X-ray showed that there was no abnormal in M4 monkey at 5 dpr, similarly prior to the re-exposure (28 dpi). Therefore, our results suggested that the monkeys with SARS-CoV-2 infection after recovery could not be re-infected with the same strain. Longitudinally, the monkey undergone single infection in this study did not appear the recurrence after the recovery either.

It has been reported that the high levels of neutralizing antibodies have a protective effect on SARS-CoV infection, but the low neutralizing antibody are more susceptible to enhance the SARS-CoV infection and trigger antibody-dependent enhancement (ADE) effect⁶. As shown in Table 1, the titers of 1:16 (M2, M4) and 1:8 (M3) exhibited the neutralizing effect at 21 dpi and 28 dpi. After the re-exposure, the titers for M4 elevated 1:40 at 5 dpr and 14 dpr, while M3 maintained the same titer as 1:8 at 5 dpr. In this study, ADE were not found in infected monkeys that were subsequently exposed to SARS-CoV-2. Because the neutralization antibody from our animal test is

comparable to that from recovered patients, this finding will have important implications to evaluate vaccine development.

From our current longitudinal study of monkeys, the reinfection could not occur if the monkeys produced the neutralizing antibody at an early stage after the primary infection. Correspondingly, the convalescing patients won't be contagious when they build up the enough specific antibody to develop immunity to SARS-CoV-2. On the other hand, no viral replication in all primary tissues was detectable in re-exposed monkeys, implying that the coronavirus might not be hidden for a long time. For the phenomenon on the discharged patients tested positively, it may be attributed to the "false negative" RT-PCR test results before their discharge or the patients without fully recovery albeit they met the discharge criteria. Therefore, further refinement of the diagnostic techniques, antibody monitoring and samples testing from the lower respiratory tract is essential for the cure of SARS-CoV-2 infection. In this study, our results indicated that the primary SARS-CoV-2 infection could protect from subsequent exposures, which have the reference of prognosis of the disease and vital implications for vaccine design. Importantly, the unsuccessful rechallenge in NHP models suggested that the re-positivity from discharged patients could not be due to reinfection. It needs to consider more complicated issues to find out the causes.

REFERENCE

1. Zhu N, Zhang D, Wang W, et al. A Novel Coronavirus from Patients with Pneumonia in China, 2019. *N Engl J Med* 2020;10.1056/NEJMoa2001017.
2. Coronavirus disease 2019 (COVID-19) Situation Report. 2020. at https://www.who.int/docs/default-source/coronaviruse/situation-reports/20200311-sitrep-51-covid-19.pdf?sfvrsn=1ba62e57_4.)
3. Lan L, Xu D, Ye G, et al. Positive RT-PCR Test Results in Patients Recovered From COVID-19. *JAMA* 2020.
4. Zhou L, Liu Q, Liu HG. Novel coronavirus pneumonia patients' recurrence after discharge: Causes Analysis and treatment strategies. *Chin J Tuberc Respir Dis* 2020;43.
5. Diagnostic and treatment protocol for Novel Coronavirus Pneumonia (Trial version 7). 2020. at <http://www.nhc.gov.cn/yzygj/s7652m/202003/a31191442e29474b98bfed5579d5af95.shtml>.)
6. Wang SF, Tseng S-P, Yen C-H, et al. Antibody-dependent SARS coronavirus infection is mediated by antibodies against spike proteins. *Biochemical & Biophysical Research Communications*;451:208-14.
7. Bao L, Deng W, Huang B, et al. The Pathogenicity of SARS-CoV-2 in hACE2 Transgenic Mice. *bioRxiv* 2020:2020.02.07.939389.

Table 1 Neutralizing antibody titers to protect of SARS-CoV-2-infected Monkeys from reinfection.

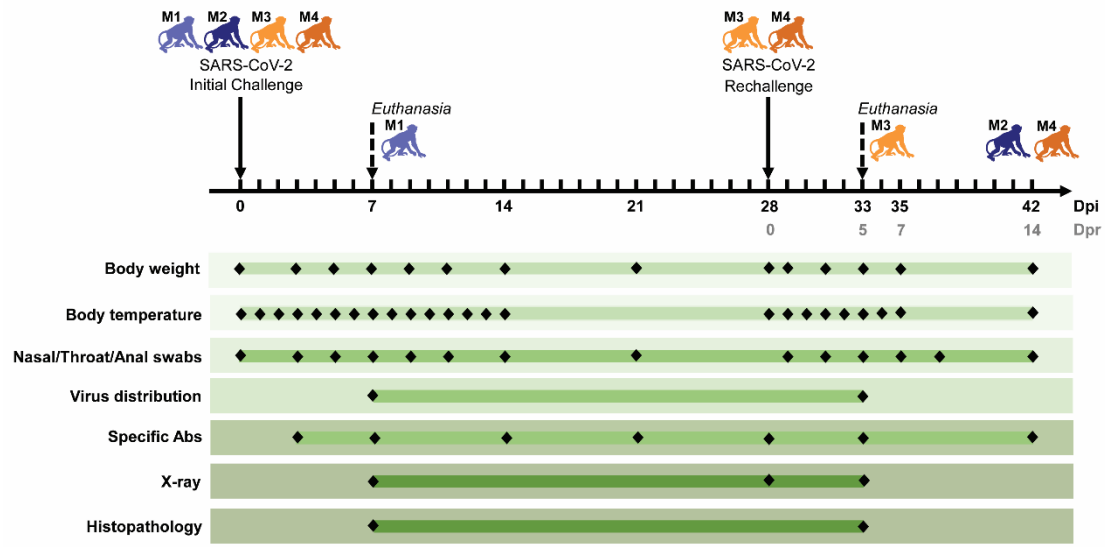
Animal ID	Primary challenge		Rechallenge	
	21 dpi	28 dpi	5 dpr	14 dpr
M1 ^a	NE	NE	NE	NE
M2 ^b	1:16	1:16	NE	NE
M3 ^c	1:8	1:8	1:8	NE
M4	1:16	1:16	1:40	1:40

Notes: a M1 was euthanized and necropsied at 7 dpi. NE, not examined.

b M2 was continuously monitored without rechallenge. NE, not examined.

c M3 was euthanized and necropsied at 5 dpr. NE, not examined.

160



161

162 **Figure 1 Experimental design and sample collection.** Four monkeys were initially
163 challenged with 1×10^6 TCID₅₀ SARS-CoV-2 with the intratracheal route. To investigate
164 the influence of reinfection, M3 and M4 after recovery were intratracheally
165 rechallenged with the same dose of SARS-CoV-2 at 28 days post-infection (dpi). Two
166 animals (M1 and M3) were sacrificed at 7 dpi and 5 days post-rechallenge (dpr),
167 respectively. M2 with single infection and M4 with primary infection followed by
168 secondary challenge were longitudinally monitored during the entire observation. Body
169 weight, body temperature and nasal/throat/anal swabs were measured along the
170 timeline at a short interval. Two measurements of virus distribution and histopathology
171 (HE/IHC stain) were carried out at 7d dpi (M1) and 5 dpr (M3). The specific antibodies
172 against SARS-CoV-2 were detected seven times and X-ray was examined three times.

173

174

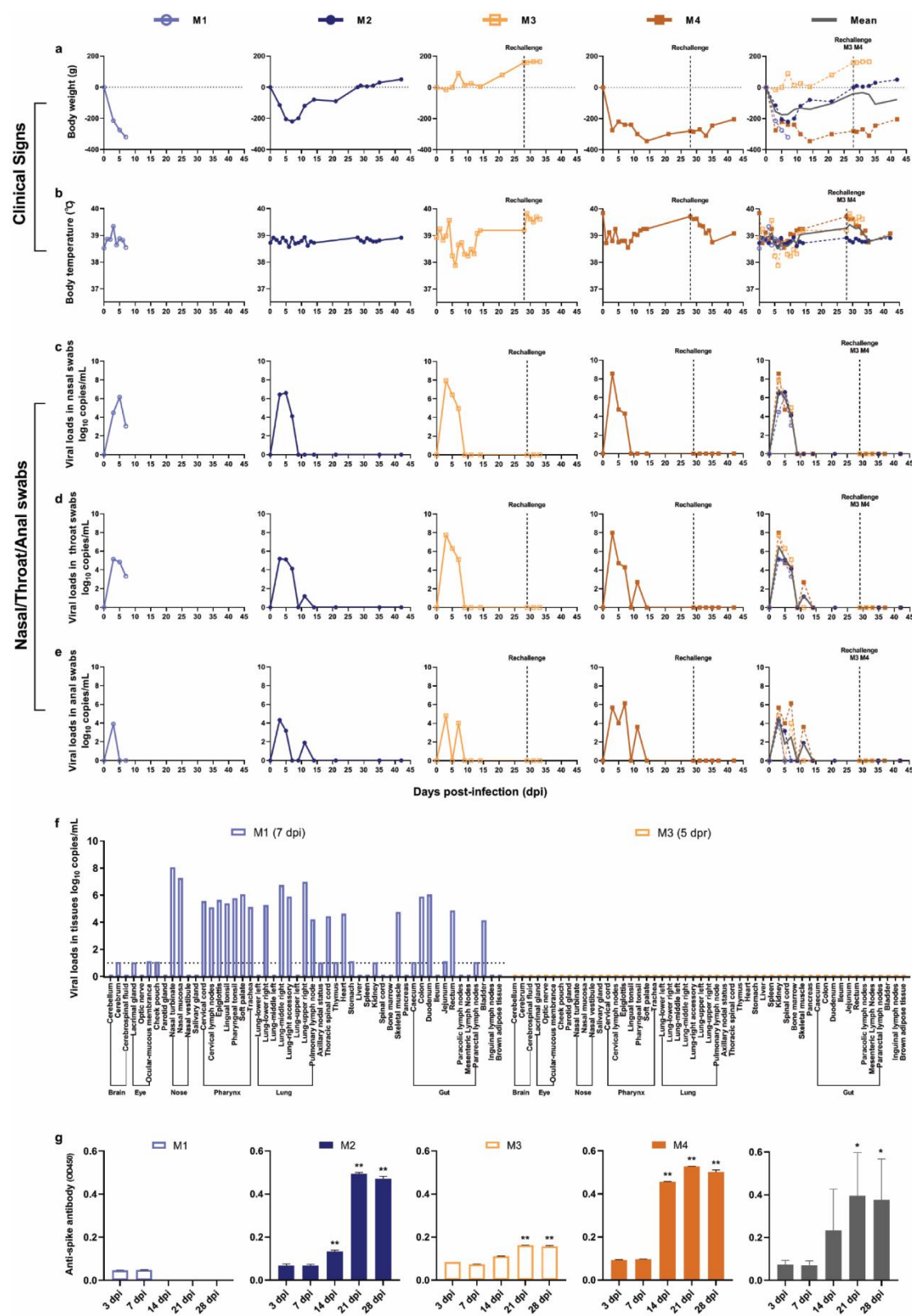


Figure 2 Longitudinally tracking in clinical signs, viral replication and immune response. (a and b) Clinical signs in each monkey. Monkeys were recorded daily for the changes in body weight and rectal temperature along the timeline after the initial

infection followed by the virus rechallenge. Weights were expressed as percentage of body weight prior to primary infection. (c, d and e) Detection of viral RNA in nasal swabs, throat swabs and anal swabs. SARS-CoV-2 RNA was detected by qRT-PCR in the swabs from four monkeys at the indicated time points. Two monkeys were rechallenged at 28 dpi (the dotted line). (f) Detection of viral RNA in the mainly organs, such as brain, eye, nose, pharynx, lung and gut. Compared to M1 with primary infection at 7 dpi, viral replication tested negatively in the indicated tissues from M3 (at 5 dpr) with the virus rechallenge. (g) Levels of specific IgG against spike protein in each monkey. The levels of anti-viral antigen specific IgG from each monkey were detected at 3, 7, 14, 21, 28 dpi. The level of specific IgG at 14 dpi, 21 dpi or 28 dpi was significantly higher than that at 3 dpi or 7 dpi. The grey lines or bars represented the average of all animals at the indicated time points. (One-way ANOVA, $*P<0.05$, $**P<0.01$)

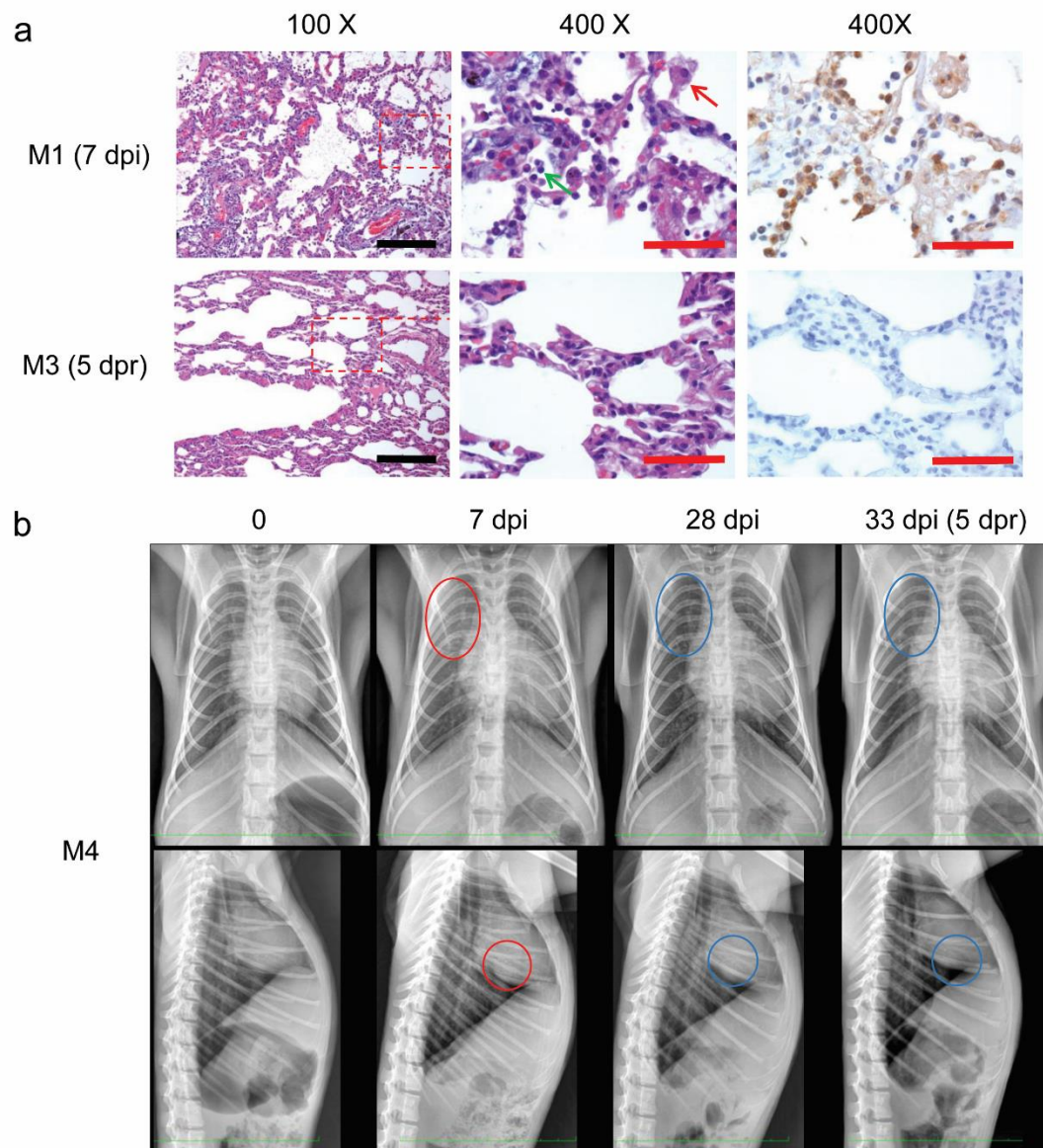


Figure 3 Longitudinally tracking in histopathology and chest X-ray. (a) Histopathology and immunohistochemical examination of lung in M1 monkey (7 dpi) and M3 monkey (5 dpr). Histopathological examination exhibited that moderate interstitial pneumonia with infiltration of lymphocytes (green arrow) and swollen alveolar macrophages (red arrow) in the alveolar cavities at 7 dpi. The antigen of SARS-CoV-2 were detected with anti-Spike antibody using immunohistochemical examination. Black scale bar=100 μ m, red scale bar=50 μ m **(b)** Longitudinal examination of Chest X-ray in M4 monkey. M4 monkey were tested by chest X-ray

203 prior to the challenge, as well as 7 dpi, 28 dpi and 5 dpr. Front chest X-ray (upper panel),
204 Lateral chest X-ray (lower panel).

205

206

Methods

Ethics statement

Four 3- to 5-year old rhesus macaques, named as M1 to M4, were housed and cared in an Association for the Assessment and Accreditation of Laboratory Animal Care (AAALAC)-accredited facility. All animal procedures and experiments were carried out in accordance with the protocols approved by the Institutional Animal Care and Use Committee (IACUC) of the Institute of Laboratory Animal Science, Chinese Academy of Medical Sciences (BLL20001). All animals were anesthetized with ketamine hydrochloride (10 mg/kg) prior to sample collection, and the experiments were performed in the animal biosafety level 3 (ABSL3) laboratory.

Animal experiments

For primary infection, all animals were inoculated intratracheally with SARS-CoV-2 (SARS-CoV-2/WH-09/human/2020/CHN isolated in our laboratory) stock virus at a dosage of 10^6 TCID₅₀/1 mL inoculum volume. After the recovery, M3 M4 were rechallenged intratracheally with the same dose (10^6 TCID₅₀/1 mL inoculum volume) SARS-CoV-2 at 28 dpi. To confirm the virus distribution and pathological changes, M1 at 7 dpi and M3 at 33 dpi (5 dpr) were euthanasia and autopsied respectively. All animals were monitored along the timeline to record body weights, body temperature, clinical signs, nasal/throat/anal swab, X-ray and specific antibody. The animal experiment and longitudinal sampling schedule are shown in Figure 1.

Quantification of SARS-CoV-2 RNA

The nasal/throat/anal swab samples and mainly tissue compartments collected from infected monkeys were tested for SARS-CoV-2 RNA by quantitative real-time reverse

transcription-PCR (qRT-PCR). Total RNA was extracted and reverse transcription was performed as previously described⁷. qRT-PCR reactions were carried out on an ABI 9700 Real-time PCR system (Applied Biosystems Instrument), the cycling protocol and the primers as follows: 50°C for 2 min, 95°C for 2 min, followed by 40 cycles at 95°C for 15 s and 60°C for 30 s, and then 95°C for 15 s, 60°C for 1 min, 95°C for 45 s. Forward primer: 5'-TCGTTTCGGAAGAGACAGGT-3', Reverse primer: 5'-GCGCAGTAAGGATGGCTAGT-3'.

ELISA

Sera were collected from each animal for the measurement of SARS-CoV-2 antibody by enzyme-linked immunosorbent assay (ELISA) along the detection timeline after the initial infection. 96-well plates were coated with 0.1 µg Spike protein of SARS-CoV-2 (Sino Biological, 40591-V08H) overnight at 4°C and blocked with 2% BSA/PBST for 1 hour at room temperature. 1:100 diluted samples were added to each well and incubated for 30 minutes at 37°C, followed by the HRP-labeled goat anti-mouse antibody (Beijing ZSGB Biotechnology, ZB-2305) incubated for 30 minutes at room temperature. The reaction was developed by TMB substrate and determined at 450 nm.

Histopathology and Immunohistochemistry

Autopsies were performed according to the standard protocol in ABSL3 laboratory at 7 dpi for M1 and 5 dpr for M3. Lung samples were fixed in 10% neutral-buffered formalin solution. Then, paraffin sections (3-4 µm in thickness) were prepared and stained with Hematoxylin and Eosin (H&E) prior to the observation by light microscopy. For immunohistochemistry (IHC) staining to identify the antigen of SARS-CoV-2, paraffin dehydrated sections (3-4 µm in thickness) were treated with an

antigen retrieval kit (Boster, AR0022) for 1 min at 37°C and quenched for endogenous peroxidases in 3% H₂O₂ in methanol for 10 min. After blocking in 1% normal goat serum for 1 hour at roomtemperature, the slices were stained with 7D2 monoclonal antibody (laboratory preparation⁷) at 4°C overnight, following with the incubation of HRP-labeled goat anti-mouse IgG (Beijing ZSGB Biotechnology, ZDR-5307) for 1 hour. Then, the slices were visualized by incubation with 3,30-diaminobenzidine tetrahydrochloride (DAB) and the image was viewed under an Olympus microscope.

Neutralizing antibody assay

Sera samples were tested for the presence of neutralizing antibody observed by cytopathic effect (CPE). Briefly, the sera from monkeys were heat-inactivated at 56°C for 30 min. Then, serially two-fold diluted sera were incubated with 100 TCID₅₀ SARS-CoV-2 for 1 h at 37°C, and added into Vero-E6 cells in a 96-well-plate. Cells were cultured for 1 week to observe for CPE and the serum dilution in which 50% of the cells were protected from infection was calculated. Each dilution of serum was tested in triplicates.

Statistical analysis

Comparisons among the groups were determined using One-way ANOVA. All data were analyzed with GraphPad Prism 8.0 software. The level of statistical significance is designated as * $p < 0.05$, ** $p < 0.01$.

ACKNOWLEDGEMENTS

This work was supported by the CAMS initiative for Innovative Medicine of China (Grant No. 2016-I2M-2-006), National Mega projects of China for Major Infectious

Diseases (2017ZX10304402) and National Key Research and Development Project of China (Grant No. 2016YFD0500304).

AUTHOR CONTRIBUTIONS

Conceptualization: C.Q.; Methodology: L.B., W.D., H.G., C.X., J.L., J.X. and Q.L.; Investigation: L.B., W.D., H.G., C.X., J.L., J.X., Q.L., J.L., P.Y., Y.X., F.Q., Y.Q., F.L., Z.X., H.Y., S.G., M.L., G.W., S.W., Z.S., W.Z., Y.H., L.Z., X.L. and Q.W.; Writing – Original Draft: J.X.; Writing –Review and Editing: C.Q.; Funding Acquisition: C.Q. and L.B.; Resources: C.Q.; Supervision: C.Q.

COMPETING INTERESTS

The authors have no competing interests to declare.



SARS-CoV-2
Initial Challenge

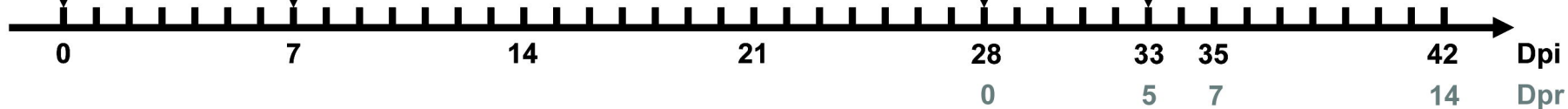


SARS-CoV-2
Rechallenge


Euthanasia




Euthanasia




Body weight




Body temperature



Nasal/Throat/Anal swabs



Virus distribution



Specific Abs



X-ray



Histopathology



